

Special Topic

Hair Transplantation in Women: A Practical New Classification System and Review of Technique

James E. Vogel, MD

Alopecia in women is often overlooked as a major cosmetic problem. For women with hair loss, the psychological effects are often more severe than for men. Advances in modern hair transplantation have allowed successful hair restoration in many cases of female alopecia that might not have been possible to treat with older techniques. A classification of female hair loss patterns into 5 different categories is proposed. On the basis of these categories, a variety of techniques are demonstrated to restore alopecia. Careful preoperative patient evaluation, including analysis of the donor and recipient features, is emphasized. In addition, women's psychological reactions to hair loss and the expectations for hair restoration are discussed. (Aesthetic Surg J 2002;22:247-259.)

For men, alopecia is a well-known cosmetic problem that can severely affect self-esteem. However, in some instances, hair loss in men can also be seen as a symbol of wisdom and maturity. In contrast, in today's society hair loss in women is neither culturally acceptable nor sexually appealing by any standards. Yet many people fail to realize hair loss in women as a significant problem. One reason for this is that the patterns of alopecia in women are generally that of diffuse thinning rather than frank baldness. In addition, women typically have more options for compensating for hair loss through styling and coloring.

Clinically, alopecia becomes a significant problem when an individual can no longer style his or her hair in a preferred manner because of insufficient hair. The incidence of hair loss in women is lower than in men. Among women older than 50, about 30 percent have significant hair loss, compared with about 50 percent of men in this age category. The incidence of female alopecia increases with age.

This article will outline some recent surgical advances that have allowed the successful treatment of women's hair loss. A practical classification for women's hair loss is presented. Hair transplantation constitutes the overwhelming bulk of hair restoration procedures in women today. Although there are special cases in which treatments such as tissue expansion and scalp reductions are applicable, these topics will not be covered here because their usefulness is limited and there is minimal *new* information in this area.

From the Division of Plastic Surgery, Department of Surgery, Johns Hopkins School of Medicine, Baltimore, MD.

Accepted for publication January 10, 2002.

Reprint requests: James E. Vogel, MD, 1838 Greene Tree Rd, Suite 420, Baltimore, MD 21208.

Copyright © 2002 by The American Society for Aesthetic Plastic Surgery, Inc.

1090-820X/2002/\$35.00 + 0

70/1/124713

doi:10.1067/maj.2002.124713

Table. Classification of female hair loss patterns

Type 1	Generalized thinning with discrete areas of alopecia in the frontal and crown vertex area
Type 2	Global diffuse thinning without discrete areas of alopecia
Type 3	Frontal temporal recession typically seen in male pattern alopecia
Type 4	Scarring alopecia
Type 5	Medical and hormonal causes (usually not surgically treated)

Patient Evaluation and Classification

Evaluation of a woman with hair loss requires a more in-depth history and work-up than evaluation of a man because of the more numerous medical and hormonal causes for alopecia in women.¹⁻⁴ Evaluation by a dermatologist, endocrinologist, or internist can be helpful when a clear explanation for the hair loss is not readily available.

Classification

Although different classification systems for hair loss in women have been proposed,⁵ there is still no system that is universally accepted or applicable, especially for surgical hair restoration. The proposed classification into 5 fundamental types of hair loss (Table) is a contemporary modification of previous attempts to categorize female hair loss. This categorization is particularly suited for the surgical evaluation and treatment of alopecia in women.

The most common pattern for hair loss in women is type 1, which was first described by Ludwig.⁵ These typical patterns are graded in terms of severity depending on the extent of alopecia (Figures 1 and 2). This type of pattern differs from those seen in men in that women usually maintain an intact frontal rim of anterior hair. In many of these patients, some degree of global scalp thinning may be present as well.

In type 2 hair loss, the hair is globally thin throughout the scalp, and focal areas of severe alopecia do not predominate (Figure 3). Patients with type 2 hair loss typically do not have good quality donor hair that is suitable for transplantation. These characteristics are detailed below. Type 3 hair loss patterns follow those seen in men with alopecia in the frontal-temporal angles and anterior hairline. The severity of alopecia in this type of hair loss varies from mild to severe (Figures 4 and 5). The final type of surgically correctable alopecia, type 4, includes

those conditions in which hair has been lost or altered because of some type of disease or traumatic scarring, surgical or manipulative process, or procedure. These causes include scars from incisions placed in the scalp, hairlines that have been shifted during surgical procedures, traction of hair by hair additions, personal hair pulling, and traumatic injuries or burns (Figures 6 and 7). Type 5 hair loss refers to conditions that are usually not amenable to surgical hair restoration.^{3,4} The most common cause in this category is chronic telogen effluvium (persistent increased telogen hair shedding). Patients in this category must be identified and not subjected to surgery, which can potentially exacerbate the alopecia.

Patients with type 1 or 2 hair loss are the most commonly seen by the hair restoration surgeon. On the basis of my clinical experience, only about 50 percent of these women are good candidates for transplantation. Contraindications to transplantation include the patient's underlying hair loss cause, the quality of the donor hair, and the patient's unrealistic expectations.

Donor and Recipient Site Evaluation

After the initial patient history and general health assessment, the first key step in patient evaluation is assessment of the donor hair. There are 6 principal qualities of donor hair that require evaluation: follicular unit density, interfollicular unit distance, hair shaft diameter, color, texture, and wave.

A hair densitometer (Ellis Instruments, Madison, NJ) is used to measure individual follicular unit density. A follicular unit is the natural in vivo number of hair shafts that exist in a single follicular grouping (Figure 8). Typically, 10 different follicular units are counted with the densitometer, and the average number of hairs per follicular group is recorded. A good candidate will have on average 2 to 3 hairs per follicular unit. If the average density of individual follicular units is less than 1.5 hairs

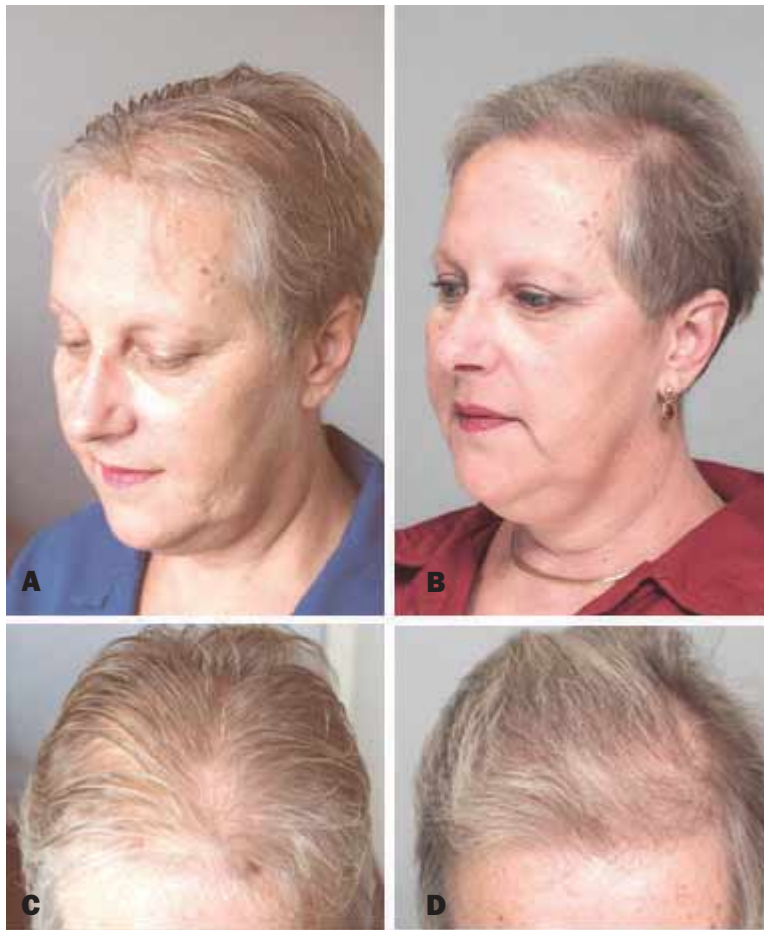

Figure 1. A, C, Type 1 hair loss, Ludwig I severity (mild). B, D, Results seen at 8 months. No additional grafts were requested. Restoration was accomplished in a single session of 600 follicular unit transplants placed into 18-G No-Kor slits to restore hairline and frontal area.

per follicular unit, it is doubtful that a follicular graft transplant procedure will produce a satisfactory result.

Interfollicular unit distance (density of in situ follicular units) and individual hair shaft diameter can be assessed objectively but are cumbersome to measure, especially during routine patient examination. A subjective assessment of these features is sufficient for daily practical use. The other donor qualities can effectively be assessed on a clinical and subjective basis as well. The rating scale we use for these features on our evaluation form is simple, rapid, and clinically useful (Figure 9). Coarse, wavy hair of large caliber will produce a thicker result and a better scalp camouflage than straight, narrow, silky donor hair. In addition to these donor hair qualities, the color of the recipient scalp has a significant bearing on the predicted outcome. For example, the less contrast between the scalp color and transplanted hair, the better the scalp

coverage. Black hair on a pale scalp allows more of a see-through appearance than blond or silver hair on an intermediate or olive-colored scalp.

The different elements of the evaluation are documented, and patients can see for themselves the qualities of the donor hair and recipient scalp that will help predict the outcome. A final “grade” is developed, in terms of a familiar scoring system, to describe the degree of scalp camouflage the donor hair is expected to produce. This evaluation is essential to determine patient suitability and to convey predicted outcome.

A discussion on future options for styling, coloring, and adding body is also integral to the patient assessment. Maximizing these post-transplantation features can clearly enhance the surgical outcome. The discussion of these types of postsurgical hair-style management is a perfect

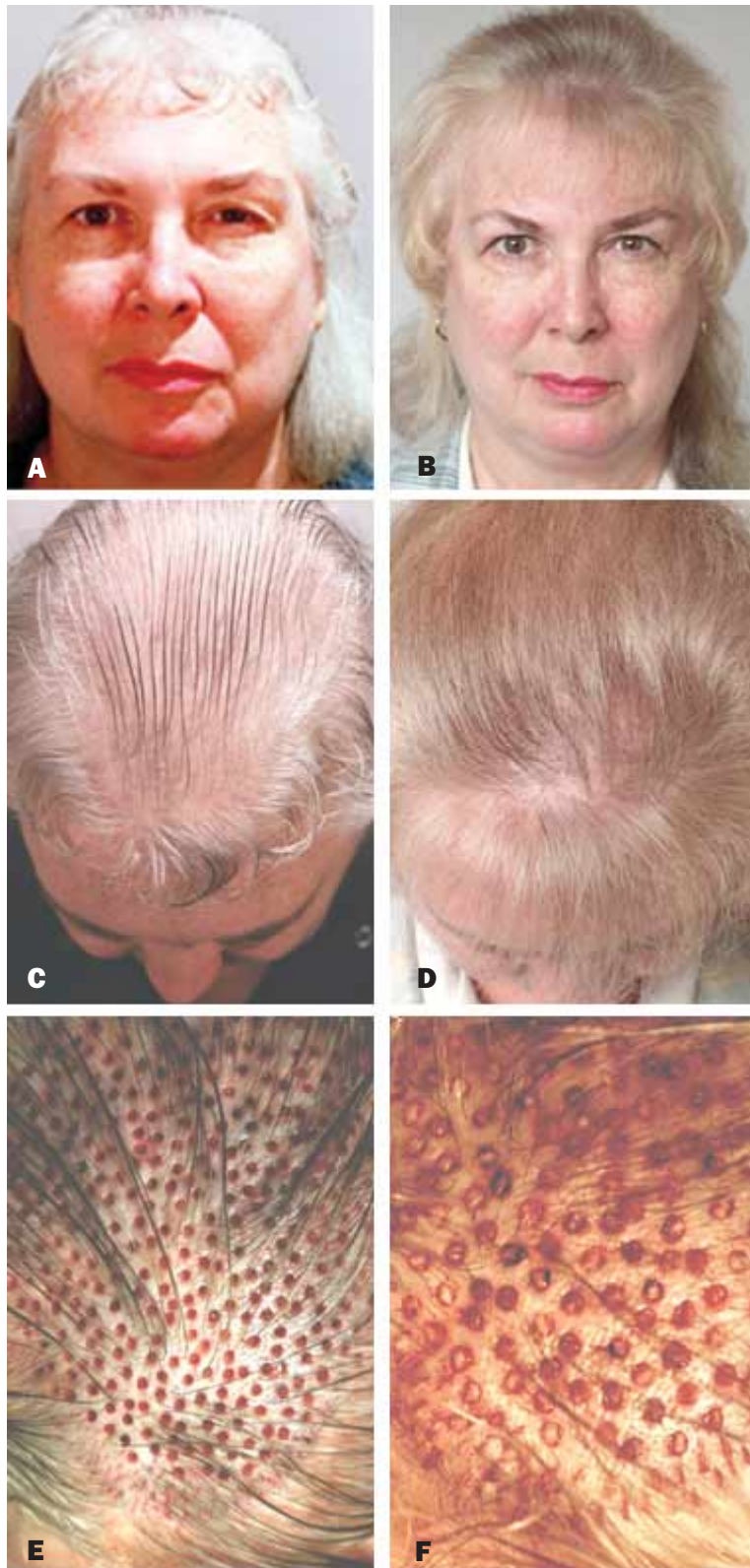

Figure 2. A, C, Type 1 hair loss, Ludwig II severity (moderate). Note the maintenance of an anterior hairline and alopecia posteriorly. **B, D,** Results are seen 1 year after the last session. **E, F,** Restoration was accomplished with follicular unit grafts placed into 18-G No-Kor slits at the hairline. Posteriorly, grafts were cut to fit into 2.5-mm holes. A total of 2 sessions were performed and a total of 1200 grafts placed.

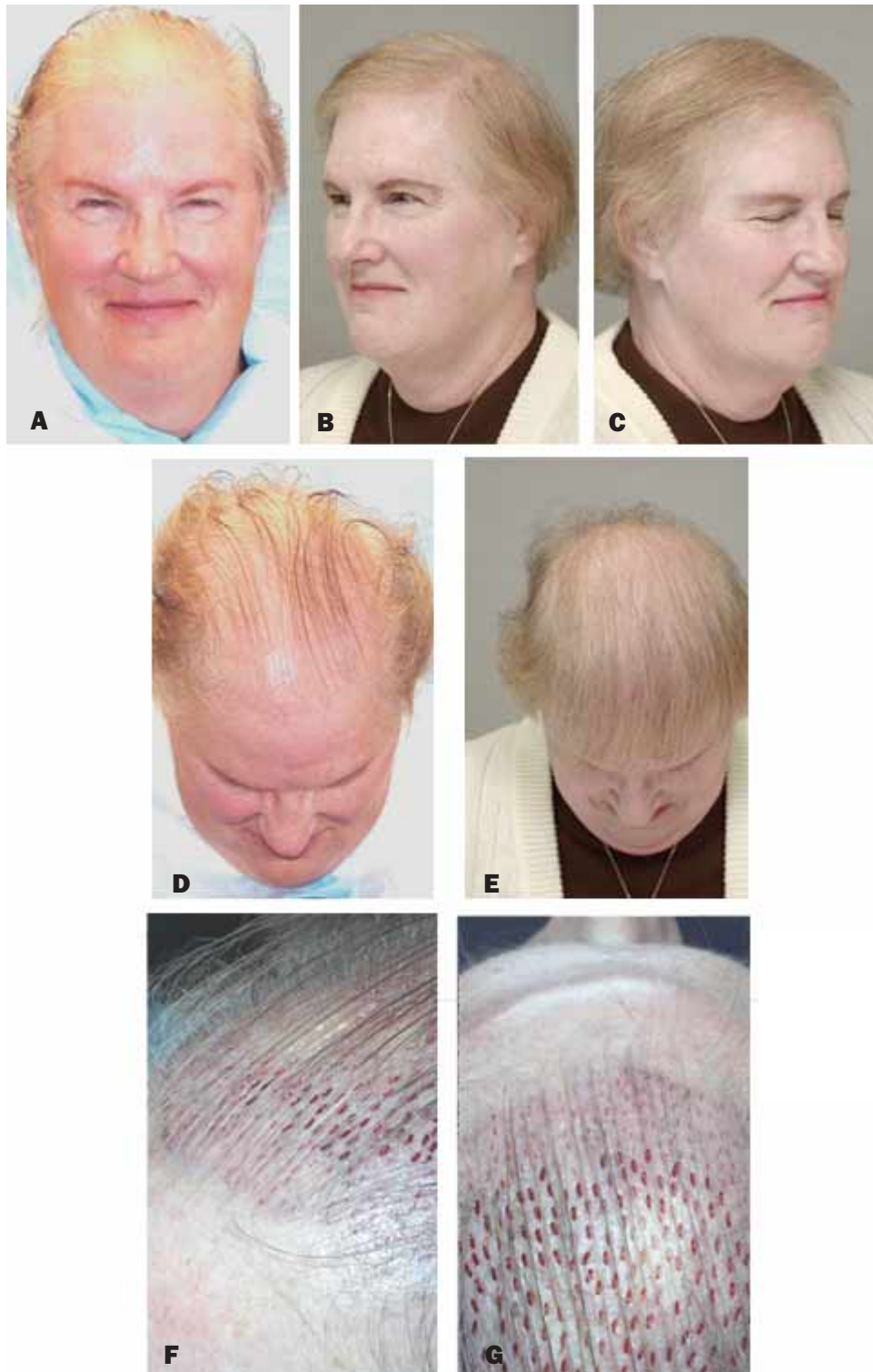

Figure 3. A, D, Type 2 hair loss (moderate to severe). Generalized thinning is observed and the donor hair is of poor quality. **B, C, E,** Results are seen 10 months after the last session. **F, G,** Hair transplantation was performed as a trial initially by placing follicular unit grafts into 18-G No-Kor slits to broadly restore the anterior hairline. Posteriorly, grafts were cut to fit into 3.25-mm ellipse-shaped slits. A total of 2 sessions were performed and a total of 1000 grafts were placed.

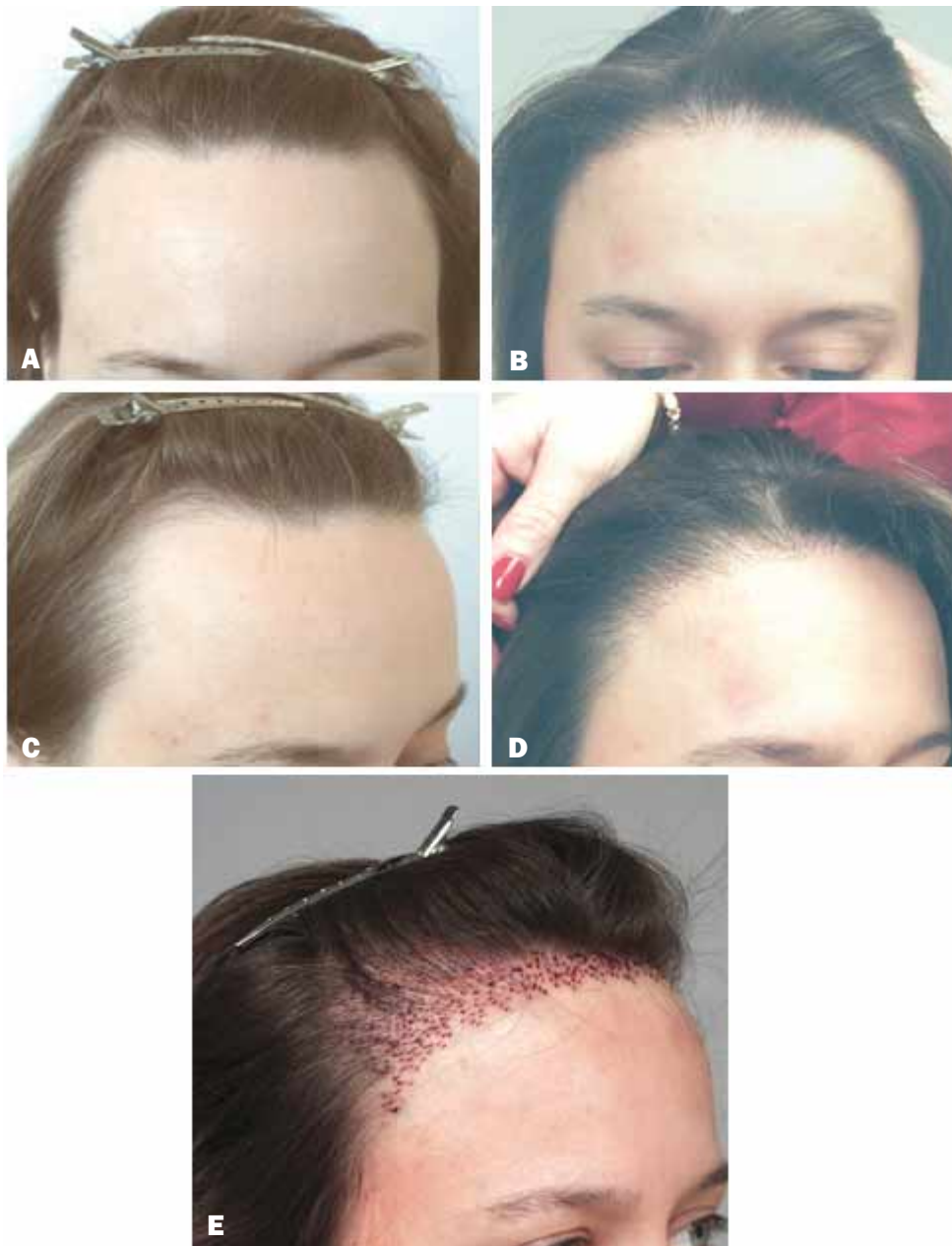

Figure 4. **A, C,** Type 3 hair loss, a male pattern of frontal temporal loss (mild). **B, D,** Results are seen 1 year after the last session. **E,** Restoration was accomplished with follicular unit grafts placed into 18-G No-Kor slits at the hairline. Note the irregular placement of grafts at the anterior hairline. A total of 2 sessions were performed and a total of 1400 grafts were placed.

lead into an evaluation of a patient's expectations and goals for transplantation.

Evaluation of Patient Expectations

In discussing realistic expectations with the female patient with alopecia, it is important to realize some of the psychosocial differences between the two sexes. Cash et al⁷ have extensively studied the psychological effects of

hair loss on both sexes and found the effects of alopecia are significantly more problematic for women than men. It has been my experience and that of others that in general, women are harder to please and have higher expectations for hair restoration than men.⁸

The results of a transplantation are almost never as thick as a woman would ideally desire. Thus it is essential to determine before operation the degree of anticipated

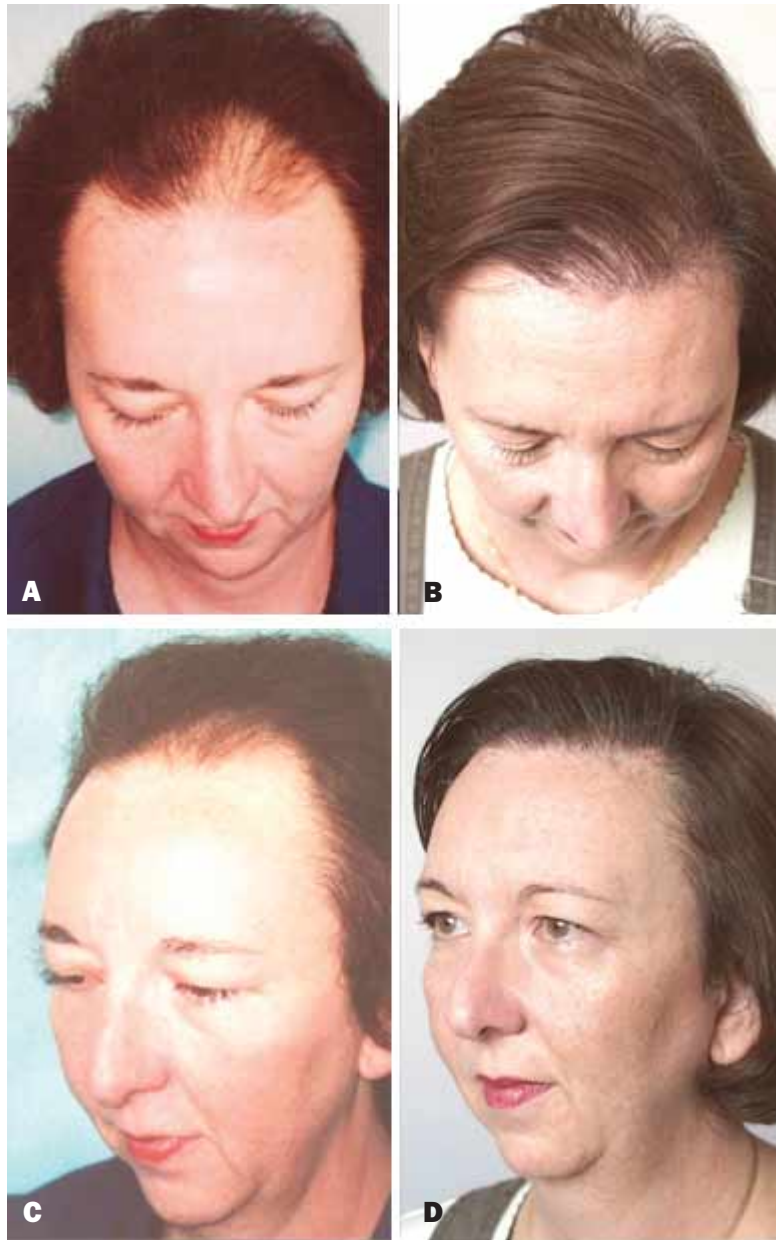

Figure 5. A, C, Type 3 hair loss, a male pattern of frontal temporal loss (moderate to severe). Restoration was accomplished with follicular unit grafts placed into 18-G No-Kor slits at the hairline. A total of 3 sessions were performed and a total of 2500 grafts were placed. **B, D,** Results are seen 18 months after the last session.

improvement. In addition, a woman's expectations and goals for hair restoration tend to be influenced to a considerable degree by the opinions and comments of friends, family members, and her hair stylist. Assessing these factors cannot be underestimated.

Finally, patients need to realize that hair loss is an ongoing process. The appreciation and assessment of future hair loss are essential to planning and patient expecta-

tion. Above all else, the surgical plan must stand the test of time to avoid iatrogenic problems in years to come.⁹

Technique

The techniques for hair restoration in women are fundamentally no different than in men. These are well described elsewhere, and only relevant details of the procedure are detailed here.^{10,11} The choice of technique to use varies

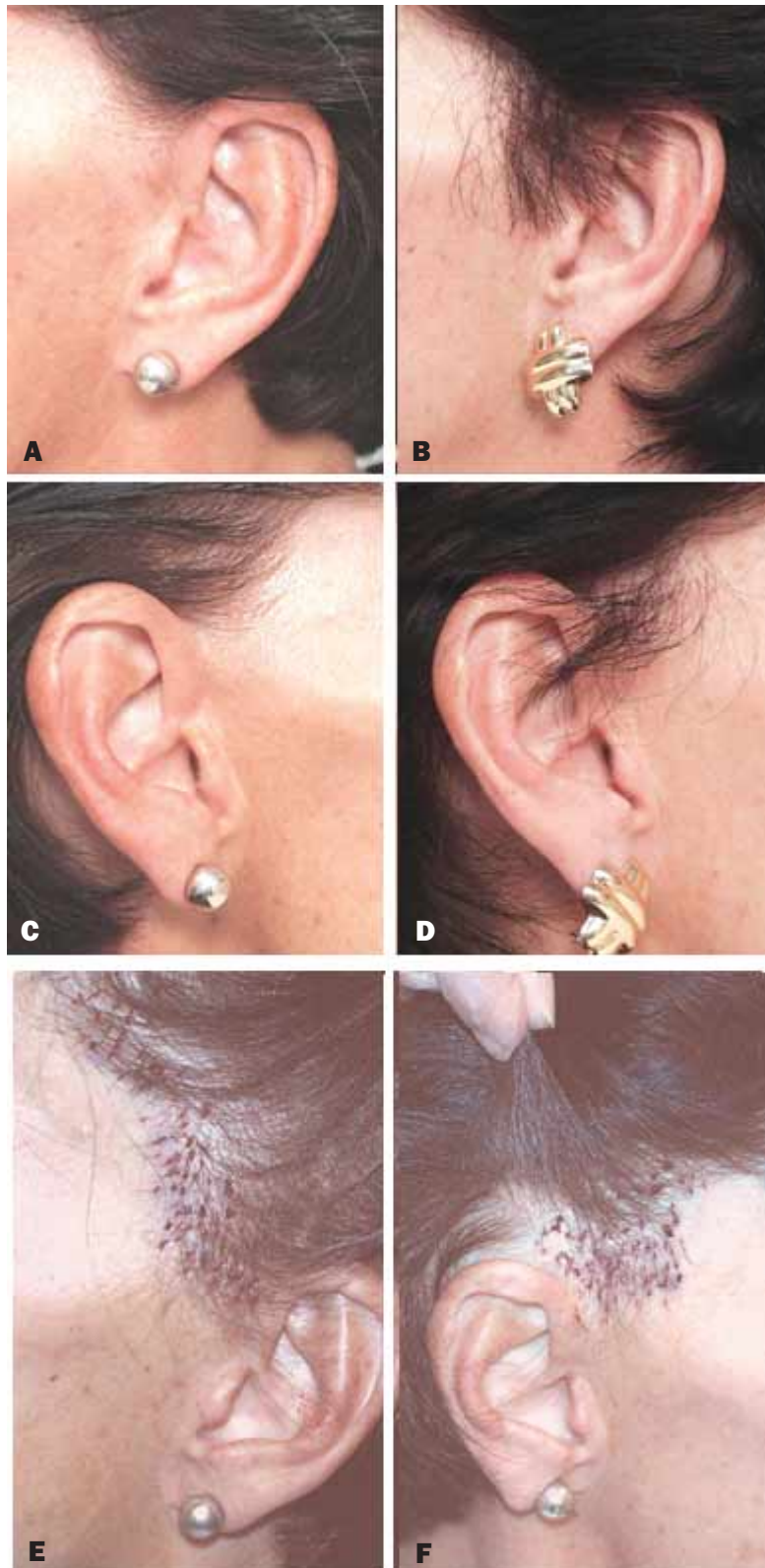


Figure 6. A, C, Type 4 hair loss, surgical hair loss, and elevation of sideburn after rhytidectomy. **B, D,** Results 1 year after surgery. **E, F,** A total of 175 follicular unit grafts were placed into 18-G No-Kor slits. No additional grafts were requested.

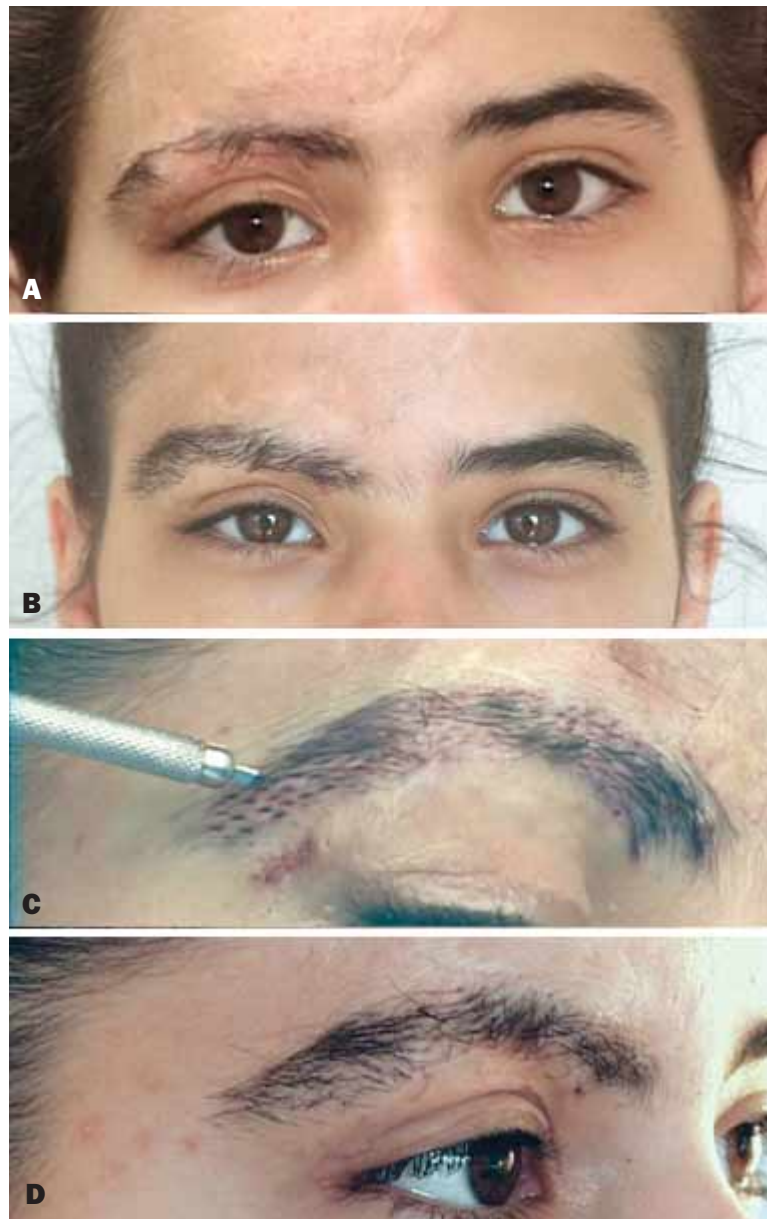

Figure 7. A, Type 4 hair loss, traumatic loss of brow hair. **B,** Results 8 months after final treatment. **C,** Restoration was accomplished in 2 sessions with a total of 225 follicular unit transplants placed into number 64 beaver blade slits. **D,** Note the angle and direction of hair growth that is established by slit origination.

according to the individual patient requirements. The determination of which technique to use is guided by the following 5 principles, which are consistent among all patients:

1. Thicken thinning areas and avoid damage to surrounding hair follicles.
2. Conserve donor hair and transplant into regions of alopecia, which will allow the maximum cosmetic coverage of recipient scalp.

3. Use grafts of different sizes to maximize characteristics of donor hair.
4. Remove bald recipient scalp if needed.
5. Minimize donor scarring.

Donor Site

The area of donor scalp that generally has the best-quality donor hair is in the occipital region just above the nuchal

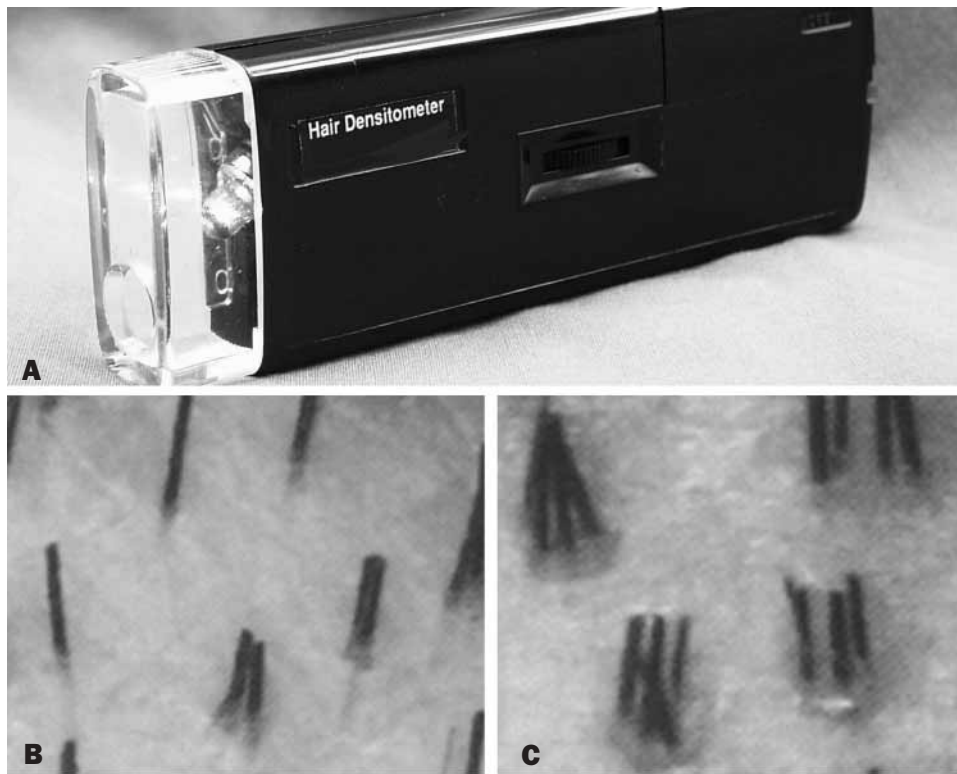


Figure 8. **A**, A hair densitometer is a specially designed magnifying device used to determine the average follicular unit density of donor hair. This is one of the important preoperative assessments. **B**, An example of poor density, 1 to 2 hairs/follicular unit. **C**, A better candidate with higher density, 2 to 3 hairs/follicular unit.

ridge. When eyebrow or sideburn transplantations are performed, softer texture hair is preferred and is usually found below the nuchal ridge or in the low parietal scalp. Strip harvesting of donor hair is preferred to the use of a multiblade knife. This technique is a faster and more efficient use of limited donor hair. In addition, an elliptical excision of donor scalp reduces the likelihood of multiblade injury to individual hair follicles during the harvest. Small-caliber (4-0) chromic suture is used to primarily close the donor wound. Cauterizing and undermining the donor wound are not performed before closure. These maneuvers can lead to in situ follicular injury, which can cause hair loss and wide scar formation.

Recipient Site

In general, recipient sites can be made with a variety of needles or small punches. The in situ recipient area hair in patients with type 1 or 2 hair loss can be especially sensitive to incisional slit injury and postoperative inflammation. This can result in considerable telogen effluvium of surrounding in situ hair (see Complications, below).

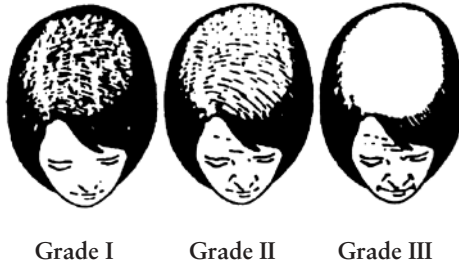
To minimize recipient trauma, 18-gauge No-Kor needles (Becton Dickinson and Co, Franklin Lakes, NJ) are preferred. Women's scalps are generally thinner than men's. Minimal depth slits (1.5 to 2.0 mm) are created to maintain 1-mm elevation of planted grafts and to reduce the likelihood of epidermal cyst formation.

The location for graft placement needs to be carefully discussed with the patient before operation and coordinated with her styling and personal preferences. The most common location for graft placement in women with type 1 or 2 hair loss is in the anterior frontal scalp. When the anterior hairline is sufficiently dense, larger grafts cut to fit into 2.0- to 2.5-mm punch holes or ellipse punches can be placed behind this area to maximize natural appearance and provide the greatest density. When the hairline needs to be reconstructed, follicular unit transplants are typically used (Figure 2).

Some patients, particularly those with type 2 hair loss, have considerable regions of recipient alopecia and very low donor density. Often these patients have donor follicle

Recipient Exam:

Scalp Color ___Olive ___Pale ___Intermediate



Grade I

Grade II

Grade III

Hair Restoration Plan:

Donor Exam:

Previous Harvest: ___ No ___Yes

Location _____

Color: ___ Brown ___ Light ___ Dark
 ___ Black ___ Blond ___ Red
 ___ Salt/Pepper ___ Other

Texture: ___ Fine ___ Coarse ___ Medium

Density: ___ Below ___ Average ___ Above

Interfollicular Dist.: ___ Below ___ Average ___ Above

Laxity: ___ Below ___ Average ___ Above

Hair Diam.: ___ Below ___ Average ___ Above

Wave: ___ Below ___ Average ___ Above

Scalp Camouflage Rating: (A-F) _____

Current Hair Status:




Figure 9. A portion of the preoperative evaluation form used for patient assessment. This approach helps to establish expectations for the patient and serves as an excellent tool for communication as well. Simple descriptive terms are used.

ular density of less than 1.5 hairs per follicular unit. For many women in this situation, the anguish of hair loss is sufficient motivation to request a transplant session, even as a trial. In selected cases recipient holes or ellipse punches are created, and large grafts (2.5 to 4.0 mm) are used. The resulting transplant does not appear pluggy because the larger grafts in these situations are carrying thin hair that has a low follicular unit density and a wide interfollicular distance. The results of this type of transplantation are modest. However, in carefully selected patients, women who are in this category are very satisfied with the outcome and request a subsequent transplantation (Figure 3). Patients with type 3 hair loss are generally approached as are patients with male pattern baldness. An irregular hairline is created with follicular unit transplant tech-

niques. Follicular units containing 1 to 2 hairs per graft are placed anteriorly, and larger grafts are positioned behind them. This creates a natural gradient of soft wispy hair leading into a fuller region. The spacing between slits is typically 1.0 to 1.5 mm (Figures 4 and 5).

Restoration of elevated sideburns after rhytidectomy is commonly requested. The outcome for this is usually very satisfactory even after a single session (Figure 6). Loss of eyebrow hair, from a variety of causes, can also be restored, but usually requires 2 or more sessions (Figure 7). Patients must be made aware that transplanted occipital hair will grow faster than their in situ brow hair and will require more frequent trimming. Careful attention to the angle of slit creation is essential to

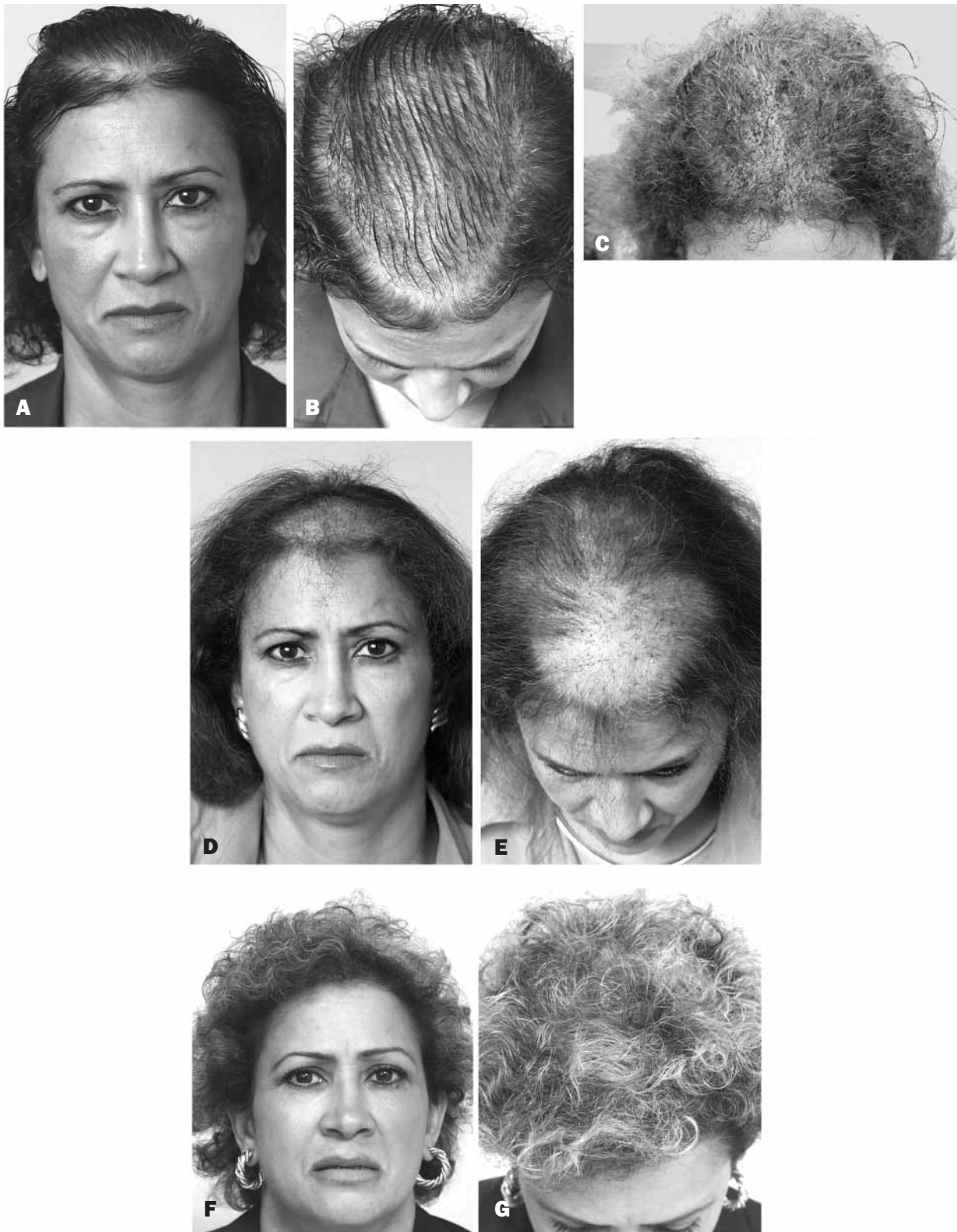


Figure 10. An example of postoperative telogen effluvium. **A, B,** Type 1 hair loss, Ludwig I severity (mild). **C,** Restoration was accomplished in a single session of 800 follicular unit transplants placed into 18-G No-Kor slits to restore the hairline and frontal area. Intraoperative view is seen. **D, E,** The patient returned at 4 weeks with considerable postoperative telogen, which resolved by 4 months postoperatively without further treatment. **F, G,** Results seen at 18 months after the transplantation. No additional sessions were requested.

enable the brow and sideburn hair to lie as flat as possible, creating a layered effect. Recipient brow slits are typically placed at about 10 degrees to the brow skin. Sideburn recipient slits are placed at about 30 degrees to the skin, with care taken to establish growth in a posterior direction (ie, toward the ear). Transplants can also be effective in helping to conceal scars in hair-bearing scalp that have resulted from surgery, burns, and other scar-producing causes. In some cases, such as treatment of coronal scars, larger grafts can produce excellent density and not produce a pluggy appearance. The quality of the recipient scalp is the main factor that predicts the success of transplant growth. Hair grafts will grow in scar tissue, but the likelihood of successful growth is in the range of 50 percent to 70 percent, whereas the likelihood in healthy scalp is at least 95 percent. Not infrequently, the texture of new hair growth is somewhat wiry. Often the texture improves after several years of growth.

Women of different ethnic backgrounds can undergo transplantation very successfully. The characteristically heavily textured hair seen in African-Americans provides excellent scalp coverage. The coarse, straight nature of Asian hair, combined with a typically olive-colored scalp, produces an excellent result as well. Black hair can look natural with larger-sized grafts, whereas the coarse texture of Asian hair appears “pluggy” if small grafts are not used.

For those individuals who request hair restoration and are not deemed suitable candidates based on physical, medical, or psychological grounds, there are limited options. These include hair additions (wigs) and scalp make-up (Couvre, Spencer Forrest Labs, Westport, CT). Medications such as minoxidil and aldactone are occasionally appropriate but have limited applicability.

Complications

Hair transplantation has a very low morbidity rate. The complications in women are similar to those in men and are discussed in detail in the cited references. Again, women’s expectations are usually higher than those of men, and thus the potential for dissatisfaction is greater. As pointed out earlier, careful patient selection can help to avoid this problem.

One important difference between hair transplants in men and women is the likelihood of postoperative telogen

of the in situ surrounding hair. Women with generalized thinning, as seen in type 1 or 2 hair loss, are particularly prone to this phenomenon (Figure 10). There are no other predictors to determine who will be more likely to have development of this temporary loss of hair in the vicinity of the transplant. In general, the telogen begins at 2 to 4 weeks after the transplantation and lasts approximately 2 to 3 months, at which time the shed hair gradually regrows. By definition, telogen is temporary, but it can be exceedingly troublesome to the patient whose hair is already scarce.

Conclusion

A full head of hair for women of all ages is the cultural norm. Recent techniques for efficient donor hair harvest and meticulous preparation of hair grafts have allowed many women to be candidates for hair restoration surgery. The artistic creation of grafts of different size and the meticulous handling of these fragile transplants have enabled treatment of some women who might not have been candidates for surgery a few years ago. Still, careful patient selection for hair restoration surgery is essential. ■

References

1. Venning VA, Dawber RPR. Patterned androgenic alopecia in women. *J Am Acad Dermatol* 1988;18:1073-1077.
2. Rushton DH. Management of hair loss in women. *Dermatol Clin* 1993;11:47-53.
3. Mortimer CH, Rushton DH, James KC. Effective medical treatment for baldness in women. *Clin Exp Dermatol* 1994;9:342-350.
4. Rushton DH, Ramsey ID. The importance of adequate serum ferritin levels during oral cyproterone acetate and ethinyl oestradiol treatment of diffuse androgen dependent alopecia in women. *Clin Endocrinol* 1992;36:421-427.
5. Ludwig E. Classification of the types of androgenic alopecia (common baldness) arising in the female sex. *Br J Dermatol* 1977;97:247-254.
6. Cotteril PC. Hair transplantation in women. In: Unger W, ed. *Hair Transplantation*. 3rd ed. New York: Marcel Dekker, Inc; 1995:287-293.
7. Cash TF, Price VH, Savin RC. Psychological effects of androgenic alopecia: comparisons with balding men and female control subjects. *J Am Acad Dermatol* 1993;29:568-575.
8. Griffin ED. The treatment of female pattern alopecia by hair transplantation. In: Stough D, ed. *Hair Replacement: Medical and Surgical*. St. Louis: Mosby-Year Book, Inc; 1996:210-216.
9. Vogel JE. Correction of the corn row transplant and other problems in hair restoration surgery. *Plast Reconstr Surg* 2000;105:2:1528-1535.
10. Unger W, ed. *Hair Transplantation*. 3rd ed. New York: Marcel Dekker, Inc; 1995.
11. Stough W. *Hair Replacement: Medical and Surgical*. St. Louis: Mosby-Year Book, Inc; 1996.